



**PATIENT PRESENTING CLINICAL SIGNS**

Hank Hippen

History: Murmur heard on initial wellness exam. Asymptomatic, newly acquired. Grade 4+ noted bilaterally.

**SPECIES ECHOCARDIOGRAM FINDINGS**

Canine

2D, m-mode, color flow and doppler imaging is available. Continuous flow detected with color Doppler in the pulmonary artery in the region of the ductus arteriosus. This cannot be confirmed on Spectral or 2D imaging; however, suspicion is high. Mild to moderate volume overload of the left heart with decreased systolic function. Increased LV sphericity. Mild to moderate LA dilation. Mild MR. No obvious TR. No pericardial or pleural effusion noted. No obvious cardiac masses.

**BREED**

Border Collie

**CARDIAC CHART**

**SEX**

Male

**AGE**

7 weeks

**WEIGHT**

7lbs

CANINE CARDIAC PARAMETERS	MR VMAX (m/s)	TR VMAX (m/s)	LA/AO (Boon method)	LA/AO (Heart Base; Swe)	FS (%)	EF (%)	EPSS (cm)
NORMAL PARAMETER	4.5-5.5	<2.7	1.3	<1.6	28-40	40-100	<0.6
PATIENT	NM	NA	NM	1.7	24	40	NM
CANINE CARDIAC PARAMETERS	HR (BPM)	AV VMAX (m/s)	PV MAX (m/s)	BODY WEIGHT (kg)	LA 2D short axis Base view (cm)	LVIDd Avg; 2D and m-mode short axis (cm)	LVIDs Avg; 2D and m-mode short axis (cm)
NORMAL PARAMETER	50-100	0.7-1.7	0.7-1.6	BELOW	BELOW	BELOW	BELOW
PATIENT	NM	NM	0.7	3.2	2.3	3.3	2.5
*Normal chamber parameters expressed as a mean value (SD)				3	1.27 (5.3)	2.46 (2.46)	1.36 (5.5)
<b>BODY WEIGHT DEPENDENT PARAMETERS</b>				5	1.40 (4.5)	2.74 (5.2)	1.60 (4.7)
<i>*Note: All measurements based upon multi-modal images and methods. An average value is reported.</i>				10	1.50 (3.8)	3.27 (3.5)	2.06 (3.1)
				15	1.83 (2.0)	3.71 (2.4)	2.43 (2.1)
				20	2.02 (1.9)	4.14 (2.2)	2.80 (2.0)
				25	2.18 (2.4)	4.48 (2.9)	3.10 (2.5)
				30	2.33 (3.3)	4.83 (3.9)	3.39 (3.4)
				35	2.48 (4.3)	5.17 (5.0)	3.69 (4.5)
				40	2.62 (5.2)	5.48 (6.1)	3.96 (5.4)
				50	2.88 (7.1)	6.07 (8.3)	4.46 (7.4)

**INTERPRETED BY**

Maggie Machen Lamy, DVM, DACVIM (Cardiology)

**IMAGING PERFORMED BY**

Sarah Meyers, DVM

**HOSPITAL NAME**

Red Hills Veterinary Hospital

**REFERRING VET**

Dr. Gotfredson

**INVOICE**

21033

**DATE**

9/14/21

**INTERPRETATION OF THE FINDINGS & FURTHER RECOMMENDATIONS**

The cause of the murmur is suspected to be a patent ductus arteriosus (PDA). This is a congenital condition where a blood vessel present in the fetus remains open after birth. When patent, this allows blood to recirculate through the lungs inappropriately and volume overloads the left heart chambers as is seen here. The diagnosis is considered suspect as the ductus is not visualized nor is Spectral accurately assessed; however, color doppler is suspicious. It is important to note that additional congenital defects can be easily missed in these cases, and advanced imaging with a Cardiologist is strongly recommended.

Given LA/LV dilation, this patient is at risk for progression to CHF, arrhythmias, PDA reversal due to development of pulmonary hypertension, exertional syncope, and/or sudden death at home in the future. Monitor sleeping respiratory rates at home to screen for progression to CHF.



## PATIENT

Hank Hippen

## SPECIES

Canine

## BREED

Border Collie

## SEX

Male

## AGE

7 weeks

## WEIGHT

7lbs

## INTERPRETED BY

Maggie Machen Lamy,  
DVM, DACVIM  
(Cardiology)

## IMAGING PERFORMED BY

Sarah Meyers, DVM

## HOSPITAL NAME

Red Hills Veterinary  
Hospital

## REFERRING VET

Dr. Gotfredson

## INVOICE

21033

## DATE

9/14/21

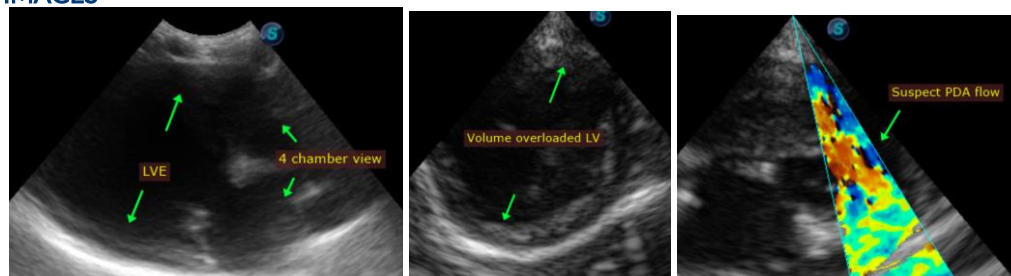
Gold standard therapy is surgical closure of the vessel. This can be done interventionally or through a thoracotomy, and consultation with a local Cardiologist is recommended if sought (**highly recommended**). Success rates for the procedure are generally high, particularly given the asymptomatic status and a good chance for a normal life if closed appropriately. Regardless of whether or not surgery is elected, cardiac support with Pimobendan is recommended for long term benefit. If surgery is not an option, prognosis is guarded to poor long term and close monitoring is advised.

Omega fatty acid supplementation and mild salt restriction may be of some long-term benefit. Monitoring of sleeping breathing rates is recommended as the best way to screen for progression to CHF at home. Mild activity restriction is advised. Monitor at home for breathing changes, worsening cough, fainting episodes, exertional dyspnea.

## PLAN

Institute Pimobendan 0.3mg/kg PO q12h (compounding likely necessary). Recommend immediate referral to a local Cardiologist for conformation of the diagnosis and surgical consultation. If not an option, reassess structure and function every 6 months lifelong to assess need for additional medications, sooner if clinical signs arise (progressive cough, labored breathing, syncope).

## IMAGES



The information and recommendations provided are based on the images presented by the referring veterinarian. No evaluation can be communicated regarding pathology that was not visible in the image/video clips provided.

Thank you for this referral. This report was generated using transcription software, and minor dictation errors may be present. If the clinical or image interpretation does not parallel your findings or if I can be of any further assistance please contact me.

Maggie Machen Lamy, DVM  
Diplomate of the American College of Veterinary Internal Medicine (Cardiology)  
info@sonopath.com